



California Pacific  
Medical Center

A Sutter Health Affiliate

Community Based, Not For Profit

# Diagnosis and Treatment of Lower Gut Motility Disorders

## COMPLEX DIGESTIVE DISEASE CENTER GASTRO-INTESTINAL MOTILITY SERVICE

At California Pacific Medical Center we are committed to bringing new and advanced diagnostic tools, medical treatments, and surgical options to the physicians we serve and the patients they care for. Through this procedure profile, our physicians illustrate actual medical situations that provide you with a window into their practice of diagnosis, treatment and patient follow-up.

For patient referrals:  
(888) 637-2762

[www.cpmc.org/gi](http://www.cpmc.org/gi)

### Lower Gut Motility Disorders

Primary care physicians spend enormous amounts of office time each year seeing patients concerning constipation or diarrhea. The majority of these complaints can be resolved with dietary changes, increased exercise, and medication modifications. However, many lower gut motility conditions involving functional disorders within the **colon**, **pelvic floor**, or **anal sphincter** require further diagnostic testing, treatment, and surgery for resolution.

### Colon Motility Disorder

#### INTRACTABLE CONSTIPATION

Intractable constipation is a major colon motility disorder. This prolonged constipation does not resolve with dietary changes or other simple therapeutic measures. Causes vary, but intractable constipation may be caused by several factors:

- abnormal colon contractions;
- anal sphincter spasm leading to a functional obstruction, or
- dysfunctional innervation of colonic, anal sphincter, or pelvic floor muscles. These abnormalities can lead to an uncoordination among the colon, anal sphincter, and pelvic floor.

Normal defecation involves coordination between colonic contractions and relaxation of three muscles—the puborectalis, the internal anal sphincter, and the external anal sphincter—allowing stool to pass. Some patients with intractable constipation are unable to relax these usually contracted muscles to defecate successfully.

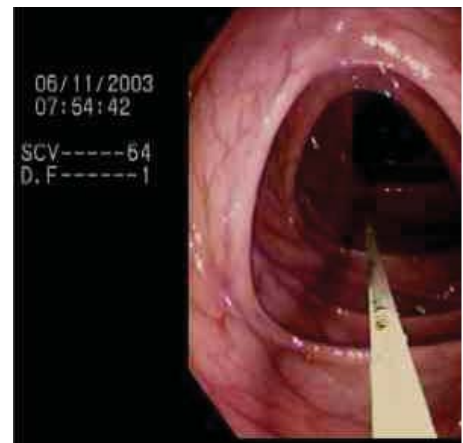
#### Intractable constipation motility conditions include:

- **Abnormal colon contractions** — chaotic and non-propulsive colon contractions do not allow for natural movement of materials through the colon.

- **Dysfunctional colonic nerves or muscles** — absence of colonic contractions due to altered neuromuscular function delays colonic transit or slow movement of materials through the colon and leads to severe constipation. Some patients with this dysfunction also complain of incomplete bowel movements.
- **Anal sphincter functional obstructions** — partial or complete failure to relax the sphincter blocks bowel content movement through the anus.
- **Pelvic floor dyssynergia (anismus)** — failure of pelvic floor muscles to have coordinated relaxation or contraction preventing normal stool elimination. In children, failure of anal sphincter relaxation can be from Hirschsprung's disease. In adults, this is often due to the lack of relaxation of puborectalis or external anal sphincter.

#### DIAGNOSTIC TESTING

Diagnostic motility testing for colon motility disorders allows physicians to visualize colonic transit and muscle condition.



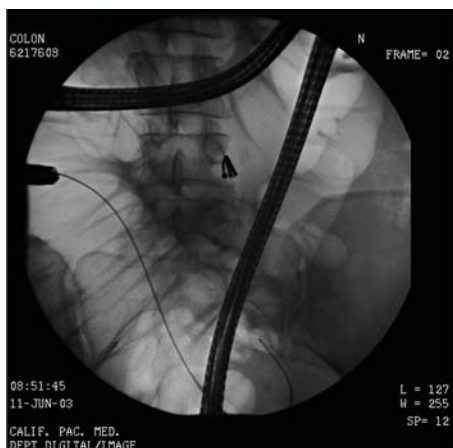
Placement of guide wire for motility catheter

- **Colonic transit studies** — Colon transit time is measured by following the movement of ingested markers with a series of x-rays. The patient swallows 24 radio-opaque markers. The markers are

*continued next page*

followed through x-rays until all the markers are eliminated or for five days. This technique allows for identification of slow or normal transit constipation, determination of site of slow transit, and follow-up of the patient's response to treatment.

- **Colonic motility** — Using a manometry pressure tube, the colon muscle strength and responsiveness to stimulation are measured. In colonic inertia the colon cannot generate contractions. This group of patients may require total abdominal colectomy for treatment of their intractable constipation. Patients with excessive contractions can be treated with medications.



Placement of colonic motility catheter

- **Colonic barostat testing** — Using a barostat, the tone and stretch of colon muscles and coordination of colon muscles are measured.

## TREATMENT

It is important to determine whether a patient has slow or normal transit constipation. Normal transit constipation may be a problem with visceral sensitivity rather than a disorder of luminal propulsion. In patients with slow transit constipation, colonic motility studies demonstrate what types of medications can stimulate the colon, as various stimulants are given during the study. Since colonic motility is measured in all parts of the colon, local disturbances in motility can be

identified. In some patients, increased colon tone leads to an increased discomfort sensation, whereas in patients with decreased tone there may be a decrease of propulsive activity.

Ileorectal anastomosis surgery, often performed laparoscopically, can be the best option for patients with colonic inertia who do not have contractions of the colon after pharmacological stimulation. Patients with poor anal sphincter relaxation and evacuation disturbances can be treated using anal sphincter retraining.

## Fecal Incontinence: Pelvic Floor and Anal Sphincter Motility Disorder

Many healthy active people of all ages suffer from fecal incontinence. Pelvic floor and anal sphincter dysfunction are often the cause. Fecal incontinence is characterized by lack of bowel control and involuntary loss of solid or loose stool. This condition can impact a person's quality of life causing self imposed isolation, physical distress, and embarrassment. Fecal incontinence is often due to anal sphincter damage caused by birth trauma, nerve damage, or scarring from previous anal surgeries such as hemorrhoidectomy. Rectal prolapse, rectocele, or general weakness or sagging of the pelvic floor can also lead to fecal incontinence. Chronic diarrhea or inflammatory bowel disease are conditions that contribute to fecal incontinence by overwhelming a marginally competent sphincter.

**It is important that patients understand that fecal incontinence is not a normal aspect of aging.**

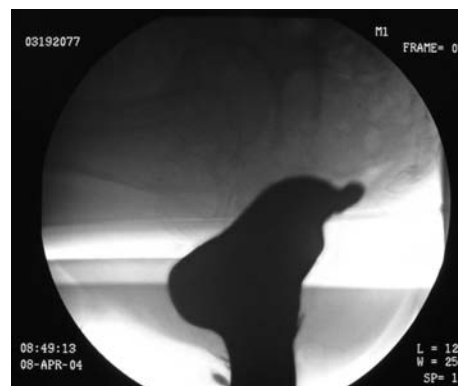## DIAGNOSTIC TESTING

Motility studies of the anorectum and pelvis in patients with fecal incontinence allow the physician to test muscle strength and nerve sensitivity.

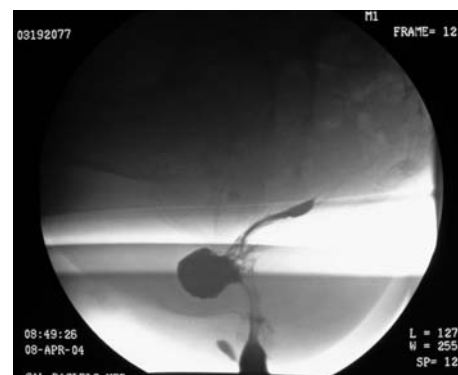- **Anal/rectal manometry** — Using a perfused catheter, the

pressure and sensation in the anus and rectum are measured in addition to measuring pelvic floor coordination.

- **Defecography** — An expert radiologist evaluates the anatomic condition of the pelvic floor and anorectal structures fluoroscopically, studying muscle contraction and relaxation during elimination of rectal barium.

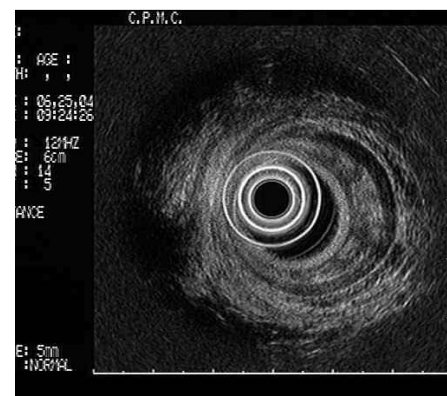


Anterior rectocele



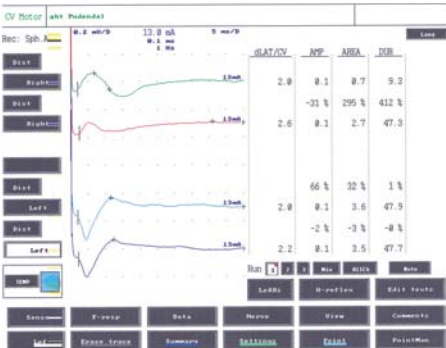Anterior rectocele that does not empty

- **Endoscopic ultrasound** — After the rectum is insufflated with air, an endoscope is utilized to look for defects in anal muscle. The integrity and size of muscle is also measured.



Anterior defect in internal and external anal sphincter

- **Pudendal nerve latency testing (PNLT)** — PNLT measures pudendal nerve conduction (electronic response) through nerve stimulation, identifying anal sphincter nerve damage and responsiveness. This test is most often used in patients with incontinence. Occasionally, however, pudendal nerve entrapment, shown by a prolonged conduction, can cause pain.



Pudendal nerve latency

## TREATMENT

**Biofeedback** — Biofeedback can play an important role in retraining the anal sphincter or pelvic floor muscles. Biofeedback is often effective for treating pelvic floor dyssynergia or other forms of intractable constipation, by retraining muscles to relax during evacuation and to contract at appropriate times. Computer feedback shows patients the pelvic floor muscle strength and provides immediate data on exercise performance accuracy. Used in conjunction with outpatient exercises, biofeedback strengthens muscles, improves coordination, and teaches patients to avoid straining.

Biofeedback allows the patient to visualize their improvement in contracting the anal sphincter. In addition, the patients are trained to contract their sphincters more rapidly.

**Bowel Training** — Relearning to control the bowels involves strengthening muscles or training the bowels to empty at a specific time each day.

**Surgery** — Surgery is only considered in the most severe cases and is

reserved for patients with debilitating symptoms who are not helped by biofeedback retraining. In some instances, the damaged area can be repaired with a simple procedure. In more complicated cases a subtotal colectomy with creation of an artificial opening (stoma) in the abdomen for removal of wastes may be the only viable treatment option.

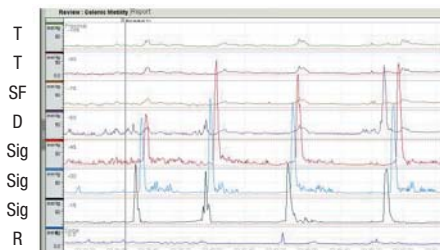
# CASE STUDIES

## 1: Prolonged Constipation

### Case Overview

A 43-year-old woman was referred with prolonged constipation. Her medical history was insignificant with the exception of anorexia in her youth. Her symptoms included abdominal pain and bloating, and lower abdominal pain when bowels had not moved for greater than three days. She was able to move her bowels daily with assistance of herbal laxative tea containing senna leaves.

### Treatment



Effect of Bisacodyl on colonic motility

A diagnostic colonoscopy was performed to evaluate the severe constipation, revealing an extremely redundant sigmoid colon with a sharp loop, which was decompressed. She also had a redundant transverse colon. Colon motility studies were done to evaluate her for the presence of colonic inertia. The transit study using radio-opaque markers showed slow transit constipation, and colonic manometry showed minimal contractions in the distal colon, suggesting colonic inertia. The patient had spontaneous contractions in the ascending

colon with erythromycin and octreotide. In addition, she had retrograde contractions after Dulcolax in the sigmoid, representing poorly coordinated motility in the lower colon.

The patient was given a prescription of Dulcolax and MiraLax with a return visit in three weeks. If medication proved ineffective, subtotal colectomy with ileoanal anastomosis would be considered. However, an anorectal manometry evaluation was performed to be sure there was no contribution of anal outlet obstruction.

Anorectal manometry was conducted to evaluate outlet difficulty in addition to poor colonic motility. The sphincter was completely symmetric with resting pressure of 88 mmHg, within normal limits. Sensory afferent tests measured first sensation at 30 cc and maximum sensation at 120 cc, placing her at marginally normal. Her pelvic floor coordination showed completely normal response.

### Outcome

The patient returned after three weeks reporting daily bowel movements with the combination medication regime of Dulcolax and MiraLax. Her abdominal pain and bloating had substantially decreased. This result was expected since she had contractions in her colon following the administration of Dulcolax.

## 2: Stool Evacuation Dysfunction, Fecal Incontinence

### Case Overview

A 57-year-old woman was referred with a chief complaint of difficulty with evacuating stool. Her medical history was significant with multiple surgeries, including hysterectomy for uterine cancer, oophorectomy, and cholecystectomy. Additionally, she had several operations for bowel obstructions. During one surgery, eight

*continued on back*

# Diagnosis and Treatment of Lower Gut Motility Disorders

inches of distal ileum was removed. Her bowel history alternated between constipation and diarrhea, with difficulty moving her bowels every two to three days. She has suffered with mild constipation for 35 years, which had become severe and incapacitating. She also complained of abdominal pain and cramping in her lower abdomen. The pain increased after eating and also included bloating. She was awakened in the middle of the night with flatus and diarrhea resulting in fecal incontinence several times a week. A previous colonoscopy revealed a tortuous and somewhat immobile colon due to multiple adhesions, as well as several diverticula.

## Treatment

A colon motility study was performed to document colonic contractions. This study showed propagating contractions that were of high amplitude, eliminating the diagnosis of colonic inertia. Anorectal manometry showed a normal sphincter and a slightly abnormal response of the pelvic floor.

## Outcome

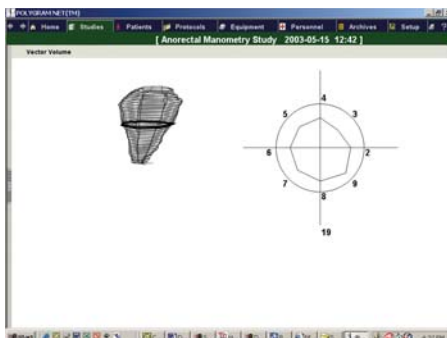
The patient was referred for anorectal biofeedback to retrain the rectal sphincter muscles. She has responded well to therapy.

## 3: Fecal Incontinence

### Case Overview

A 65-year-old man presented with a long history of fecal incontinence. The patient and his primary care physician thought his hemorrhoids were the underlying cause of the fecal incontinence. However, incontinence continued after hemorrhoidectomy and was occurring at least twice daily. He had a history of diverticular disease with a diverticular bleed, controlled epilepsy, and hypertension.

### Treatment

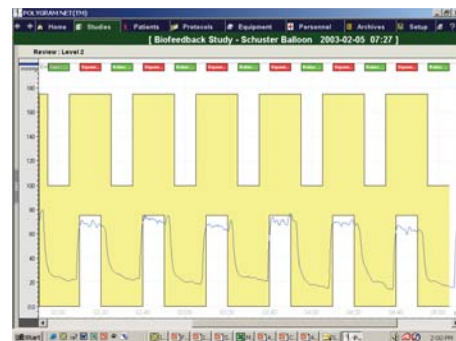


*Anal sphincter pressure: 3D image showing a symmetrical sphincter*

The patient underwent defecography, showing absence of rectocele. He also underwent endoscopic ultrasound of the anal sphincter, (showing a slightly thinned sphincter), and a pudendal nerve latency testing (showing the pudendal nerve function was within normal limits). Anorectal manometry showed decreased anal sphincter pressure. There were normal sensory afferent responses.

### Outcome

The patient received anal sphincter retraining, which did not eliminate the episodes of fecal incontinence. The patient is a candidate for sacral nerve therapy. Medtronic's InterStim sacral nerve stimulation therapy is



*Biofeedback system for improving anal sphincter competence*

currently under clinical trial at California Pacific Medical Center.

## Research

Research clinical trials are being done at California Pacific with InterStim® from Medtronic. InterStim® is an implantable device that sends mild electrical stimulation to the sacral nerves. FDA approved in 1997 for urinary incontinence, some evidence has shown that InterStim® has been effective for some fecal incontinence and evacuation difficulty.

## For more information or patient referral

Please contact our specialty referral coordinators at **(888) 637-2762** for patient referral.

If you have any questions regarding the California Pacific Motility Program please contact

**William J. Snape, Jr., M.D.**  
Medical Director  
Gastrointestinal Motility Service

Tel: (415) 600-1025  
e-mail: [snapew@sutterhealth.org](mailto:snapew@sutterhealth.org)

2340 Clay Street, 2nd Floor  
San Francisco, CA 94115

Images courtesy of William J. Snape, Jr., M.D.