



California Pacific
Medical Center

A Sutter Health Affiliate

Community Based, Not For Profit

Endosonography-Guided Pseudocyst Drainage

INTERVENTIONAL ENDOSCOPY SERVICE

At California Pacific Medical Center we are committed to bringing new and advanced diagnostic tools, medical treatments and surgical options to the physicians we serve and the patients they care for. Through this procedure profile, our physicians illustrate actual medical situations that provide you with a window into their practice of diagnosis, treatment and patient follow-up.

For patient referrals:
(888) 637-2762
www.cpmc.org/ies

What are pseudocysts?

Pancreatic pseudocysts are intra- or extra-pancreatic fluid collections composed of pancreatic secretions and inflammatory debris. Reactive granulation tissue rather than a true epithelial lining walls off the fluid collection, hence the term “pseudocyst.” Pseudocysts originate from leaks in the pancreatic duct. The etiology may be necrosis secondary to pancreatitis, progressive ductal obstruction, or trauma.

When is pseudocyst treatment indicated?

The majority of pseudocysts are asymptomatic and do not require treatment. An asymptomatic but large or enlarging pseudocyst may warrant drainage due to rupture or hemorrhage risk. Pseudocysts that complicate acute pancreatitis have a high probability to spontaneously resolve within 4 to 6 weeks and should be observed for this time period before further treatment. Earlier drainage may be indicated when clinical pancreatitis fails to improve despite aggressive medical management.

Pseudocysts complicating chronic pancreatitis usually result from pancreatic duct outflow obstruction, whether this is due to a stone, stricture, or protein plug. Such “retention” pseudocysts rarely resolve on their own. Drainage is indicated to relieve symptoms associated with a space-occupying mass and neighboring organ compression such as pain, gastric outlet obstruction, and jaundice. Drainage is also indicated when pseudocysts become infected or there is intracystic bleeding.

What are the treatment options?

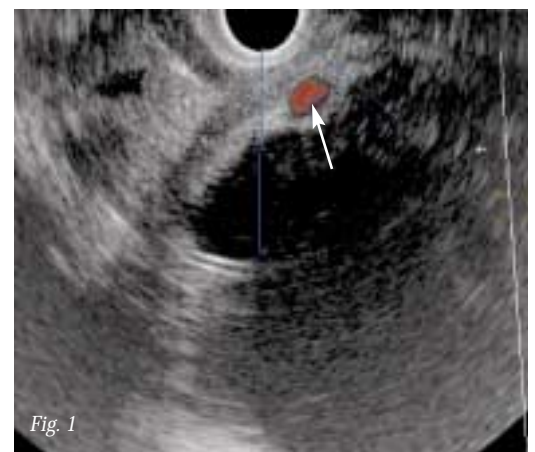Surgical drainage by cyst-gastrostomy or cyst-jejunostomy has been the standard treatment. The success rate is high, but surgical management requires an adequately mature pseudocyst wall that will hold sutures.

Percutaneous drainage has several drawbacks including skin discomfort and infection, and may leave a cutaneous fistula after drainage tube removal. Endoscopic drainage is appealing because it creates a similar result to internal surgical drainage and can treat immature pseudocysts.

How does endosonography (EUS) assist endoscopic pseudocyst drainage?

The application of EUS to guide pseudocyst puncture through the stomach or duodenal wall has improved the success and safety of endoscopic pseudocyst drainage. Using endoscopic guidance alone, a prominent mucosal bulge must be present to identify the site for pseudocyst puncture. Even then, the interposed tissue may contain vessels. EUS provides a highly detailed view of the pseudocyst and surrounding topographical anatomy. Subsurface vessels are readily detected with color Doppler.

How is EUS-guided pseudocyst drainage performed?



The optimal site for pseudocyst puncture is determined by the local EUS anatomy. Color Doppler is used to scan the area for vessels that may be interposed in the needle path (Fig. 1). Having determined the site for

continued on back page

case studies

1: Recurrent Pancreatic Pseudocyst

Case Overview

A 48-year-old woman presented with chronic mid-back pain exacerbated by movement. CT scan showed a 4 cm pseudocyst in the head of the pancreas. Three years earlier she had an attack of biliary pancreatitis, which was treated by cholecystectomy. She underwent laparoscopic cyst drainage, but the cyst recurred. She was referred to the Interventional Endoscopy Service for endosonography-guided stent drainage.

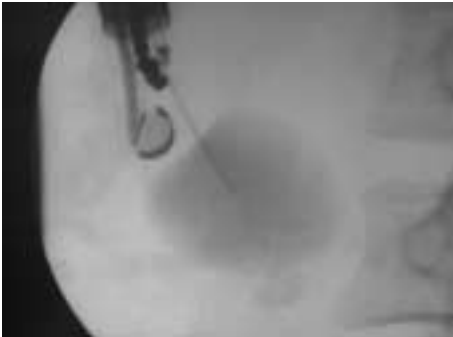

Fig. 3. Transduodenal pseudocyst opacification

Treatment

EUS identified a well-demarcated 4 cm x 3.5 cm cyst in the pancreatic head that did not communicate with the pancreatic duct (Fig. 3). The cyst was punctured transduodenal and a double pigtail stent was placed (Fig. 4). The contents were liquid and drained completely.

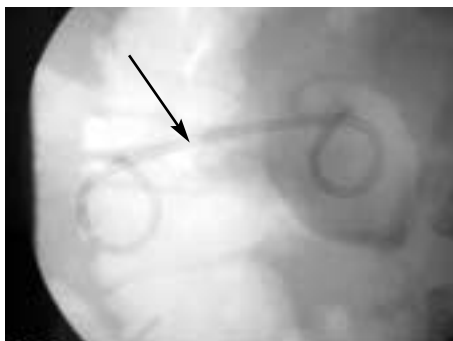


Fig. 4. Double pigtail stent

Outcome

The patient experienced immediate relief of her chronic back pain after cyst drainage. The stent was removed and she has remained pain free at 4 months follow up without pseudocyst recurrence.

2: Enlarging pseudocyst in an asymptomatic patient

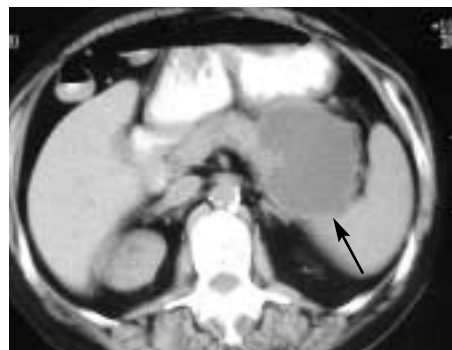

Fig. 5. Eight cm cyst in the pancreatic tail

Case Overview

A 53-year-old female with a history of alcohol abuse was diagnosed several months earlier at an outlying hospital to have a 6 cm cyst in the pancreatic tail. A follow-up CT scan showed cyst enlargement to 8 cm (Fig. 5). ERCP was performed and showed a thin pancreatic duct that communicated with the cyst. Although the patient was asymptomatic, her amylase levels remained elevated. The patient was referred to the Interventional Endoscopy Service for cyst drainage.

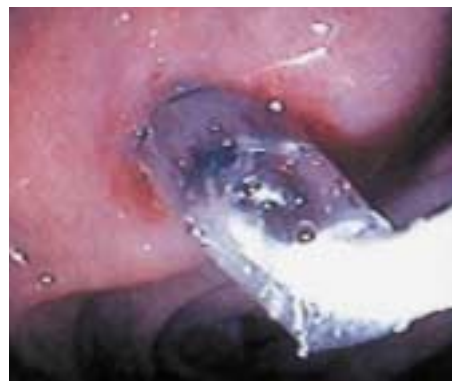

Fig. 6. Balloon dilation of cystgastrostomy (endoscopic view)

Treatment

EUS showed changes of chronic pancreatitis and a large 8.4 cm x 8.1 cm well demarcated pseudocyst in the pancreatic tail. Transgastric cyst puncture was performed and dark brown fluid contents aspirated (“chocolate cyst”). A double pigtail stent was inserted after balloon dilatation of the cystgastrostomy (Figs. 6, 7).

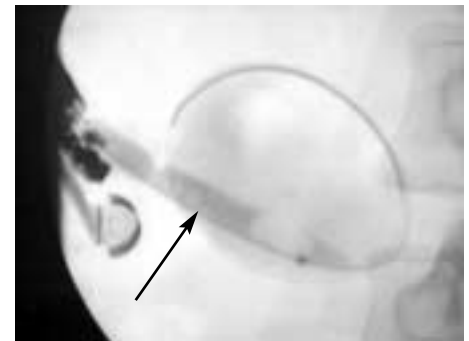


Fig. 7. Balloon dilation of cystgastrostomy (radiographic view)

Outcome

CT scan 3 weeks after stent placement showed complete cyst resolution. Pancreatic enzyme levels returned to normal. The stent was removed and the cyst has not recurred.

Comments

Asymptomatic chronic cysts showing an increase in size warrant drainage to prevent complications such as cyst rupture and bleeding.

3: Acute Pancreatitis complicated by a large pseudocyst

Case Overview

A 39-year-old male with a history of alcohol abuse was admitted to an outlying hospital with acute pancreatitis complicated by a large 9 x 7 cm pseudocyst in the pancreatic head (Fig. 8). The cyst, accompanied by diffuse abdominal pain and weight loss, persisted over a

case studies

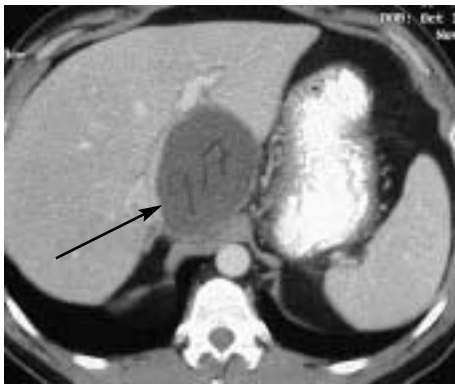


Fig. 8. Nine x 7 cm pseudocyst

6-week period. ERCP was performed and showed a stricture in the pancreatic head with upstream ductal dilation. The patient was referred to the Interventional Endoscopy Service for further evaluation and management.

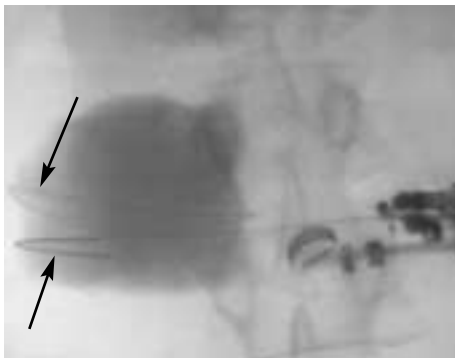


Fig. 9. Placement of 2 guidewires

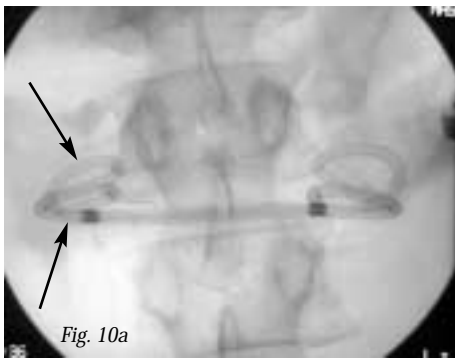


Fig. 10a

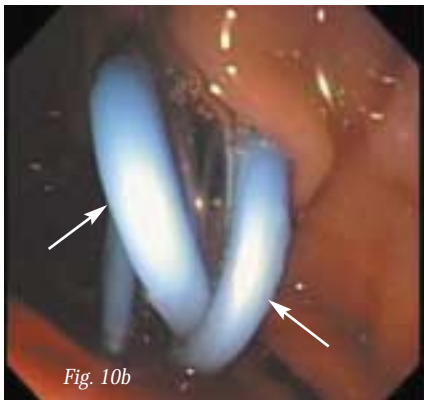


Fig. 10b

Figs. 10a & 10b. Two pigtail stents

Treatment

EUS showed diffused changes of acute pancreatitis and a large 9 cm cyst in the pancreas body. EUS-guided aspiration showed the contents to be liquid and clear. The cyst was drained with two double-pigtail stents (Fig. 9, 10a & 10b).

Outcome

The patient was discharged on oral antibiotics. A follow up CT scan one month later showed complete pseudocyst resolution (Fig. 11). His overall condition had improved, but he complained of residual right flank pain. Repeat ERCP was performed. The previously identified high-grade stricture in the pancreatic head was unchanged and could not be stented. The patient was referred for a Whipple procedure.

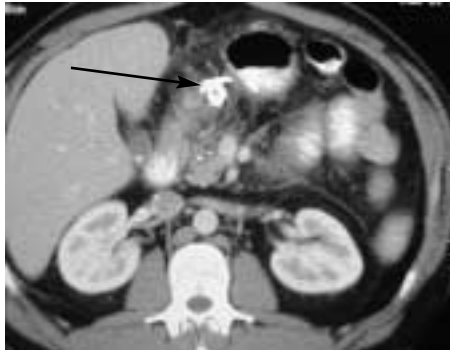


Fig. 11. Resolution of pseudocyst one month later

4: Pancreatic pseudocyst with necrotic contents

Case Overview

A 77-year-old woman was admitted to an outlying hospital with a history of increasing abdominal pain and nausea. 4 months earlier she was hospitalized with acute alcoholic pancreatitis complicated by pancreatic ascites. CT scan revealed a 9.5 x 8.0 x 7.5 cm cyst in the pancreas head. She was referred to California Pacific's Interventional Endoscopy Service for EUS-guided drainage.

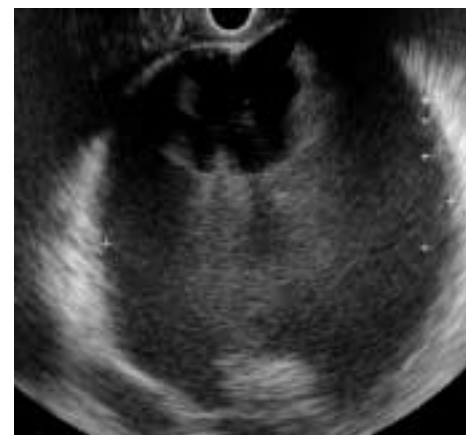


Fig. 12. Pseudocyst with necrotic contents

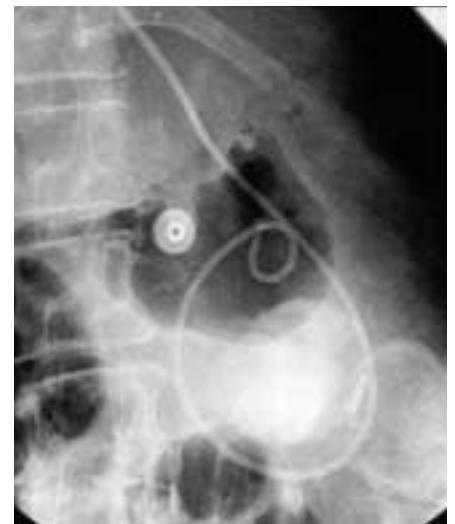

Fig. 13. Nasocystic catheter drainage

Treatment

Upper endoscopy was normal. EUS confirmed a large pseudocyst in the pancreas head and body (Fig. 12). The cyst aspirate was thick and contained necrotic debris. A nasocystic catheter was inserted to enable cyst irrigation with saline (Fig. 13).

Outcome

Daily cyst irrigation in the hospital resulted in clearing of the necrotic contents and significant clinical improvement. The nasocystic catheter was exchanged for a double pigtail stent and the patient was discharged. The stent was removed after cyst resolution. She remains asymptomatic and has resumed a regular diet.

Endosonography-Guided Pseudocyst Drainage

continued from front page

puncture, the cyst is punctured with a 19 G cyst puncture needle (*Fig. 2*). After entering the cyst, the stylet is removed and a sample of the cyst contents is aspirated for biochemical analysis and cytological examination. If the cyst appears infected an aspirate is sent for a gram stain and culture. Contrast injection under fluoroscopy is performed to document the size and anatomical boundaries of the cyst, and to identify a possible communication with the pancreatic duct. A guide wire is inserted and the drainage tract is dilated with a balloon catheter (6 mm or 8 mm). Finally, double pigtail stents are used to drain the cyst into the stomach or duodenum. If the cyst appears infected or contains necrotic debris, a nasocystic catheter is inserted for cyst irrigation. Once the cyst contents are clear, the nasocystic catheter is exchanged for a stent to maintain drainage.

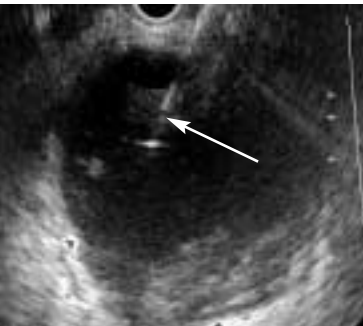


Fig. 2

What happens after stent drainage?

Patients are kept on antibiotics until complete cyst resolution is documented by computed tomography (CT). Most pseudocysts will resolve 10 to 14 days after stent drainage. The stent is removed 1 to 2 months after cyst resolution to allow the cyst wall to scar down.

Indications for EUS-guided pseudocyst drainage

- Large (> 8 cm) or enlarging cyst
- “Smoldering” acute pancreatitis
- Abdominal pain
- Symptoms of gastric outlet obstruction
- Jaundice
- Cyst infection

Advantages of EUS-guided pseudocyst drainage

- Outpatient procedure under conscious sedation
- High-resolution evaluation of cyst anatomy
- Combines diagnosis with treatment
- Identifies interposed vessels with color doppler
- Internal drainage

Sampling of pseudocyst contents

- Amylase
- Mucin stain
- CEA
- Cytology
- Culture & sensitivity (if infected)

Insurance Coverage

Medicare, Medi-Cal and most private insurance plans, covers endosonography-guided pseudocyst drainage. In order to avoid unexpected medical expenses, it is always best for patients to contact their insurance company prior to treatment to confirm coverage for this service and obtain prior authorization.

Patient referral to the Interventional Endoscopy Service

Patients need a referral from their primary care provider or physician specialist prior to scheduling endosonography-guided pseudocyst drainage evaluation and procedure. Medical records, pertinent laboratory reports, and imaging reports need to be forwarded to California Pacific’s Interventional Endoscopy Service to determine referral indication appropriateness.

For more information

Please contact the Interventional Endoscopy Service or Dr. Kenneth Binmoeller.

Kenneth F. Binmoeller, M.D.

Medical Director
Interventional Endoscopy Service
2333 Buchanan Street
San Francisco, California 94115

(415) 600-1151
email: binmoek@sutterhealth.org
www.cpmc.org/ies

For Patient Referrals
1 (888) 637-2762